

THE DISTANCE BETWEEN THE ACL AND PCL MEASURED BY LASER THREE-DIMENSIONAL SCANNING. A CADAVERIC STUDY



Cesar A. Q. Martins

Sheila J Ingham

Pisit Lertwanich

Patrick Smolinski

Freddie H Fu



Department of Orthopedic Surgery,
University of Pittsburgh, Pittsburgh, PA

Disclosure: Research/Education grant from Smith & Nephew

Background

- Several anatomical studies have assessed the anatomy of ACL bundles to clarify their insertion sites.
- The “over-the-back ridge” (OBR) is a consistent structure, which is in contact with the anterior border of the posterior cruciate ligament when the knee is in flexion.

Hutchinson MR, Bae TS (2001). Am J Sports Med.

Edwards A, Bull AM, Amis AA (2007). Knee Surg Sports Traumatol Arthrosc.



Background

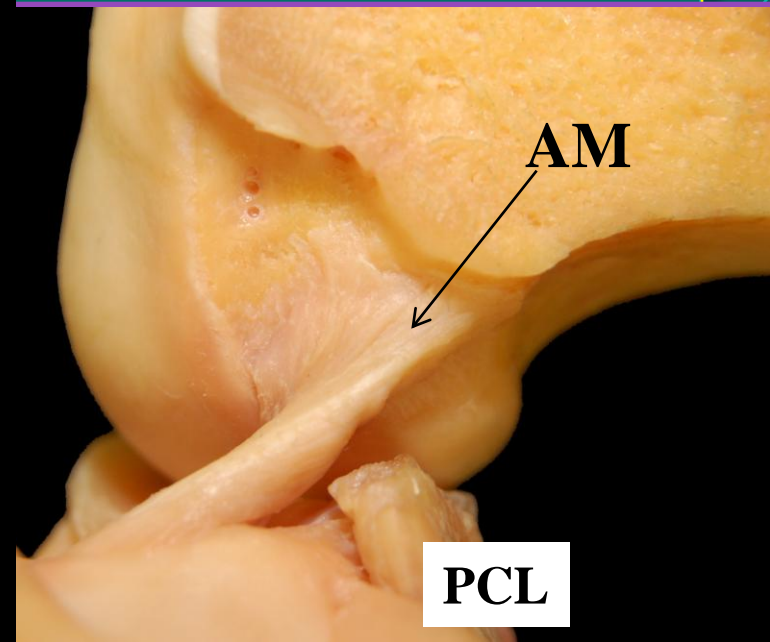
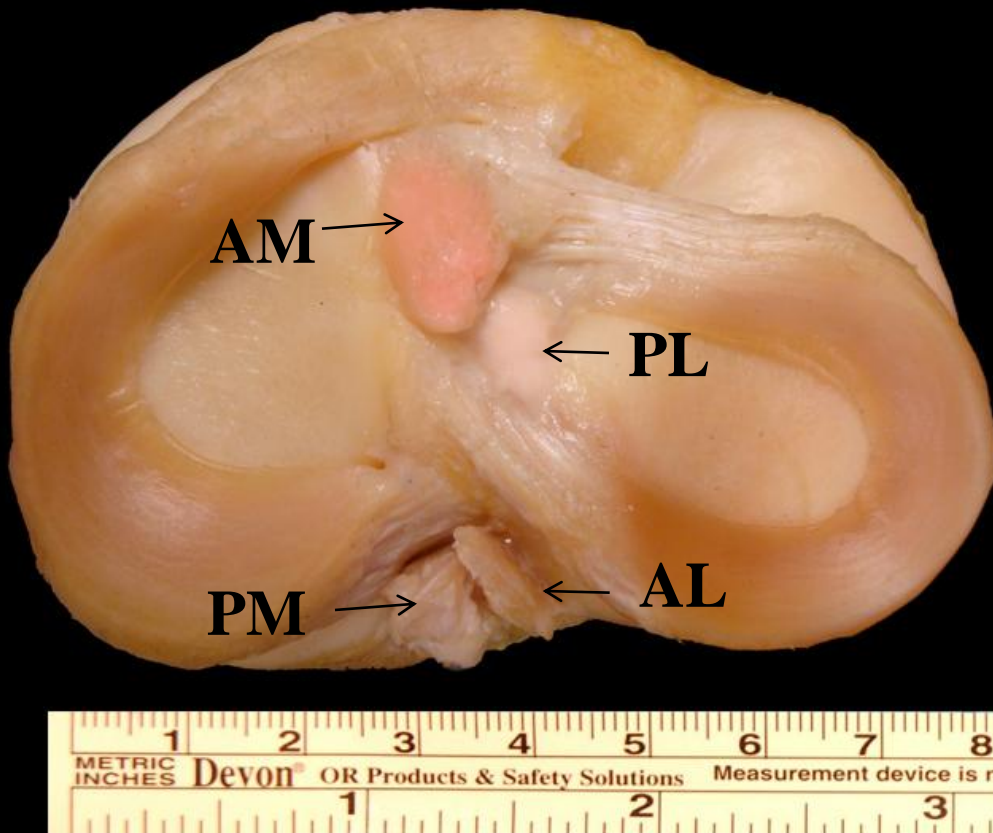
- OBR is the transverse interspinous ridge on the apex of the posterior slope of the tibial plateau, just anterior to the posterior cruciate ligament (PCL).

Hutchinson MR, Bae TS (2001). Am J Sports Med.

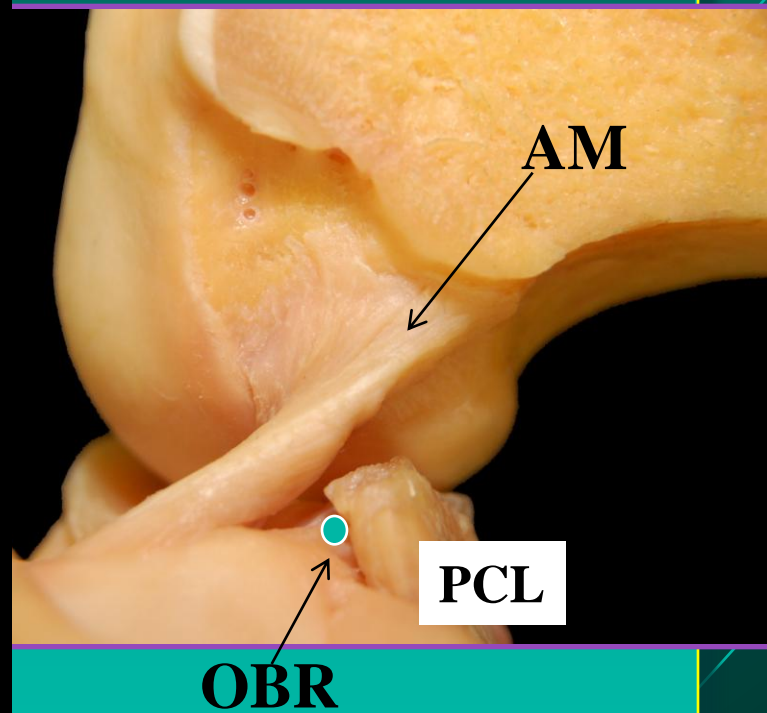
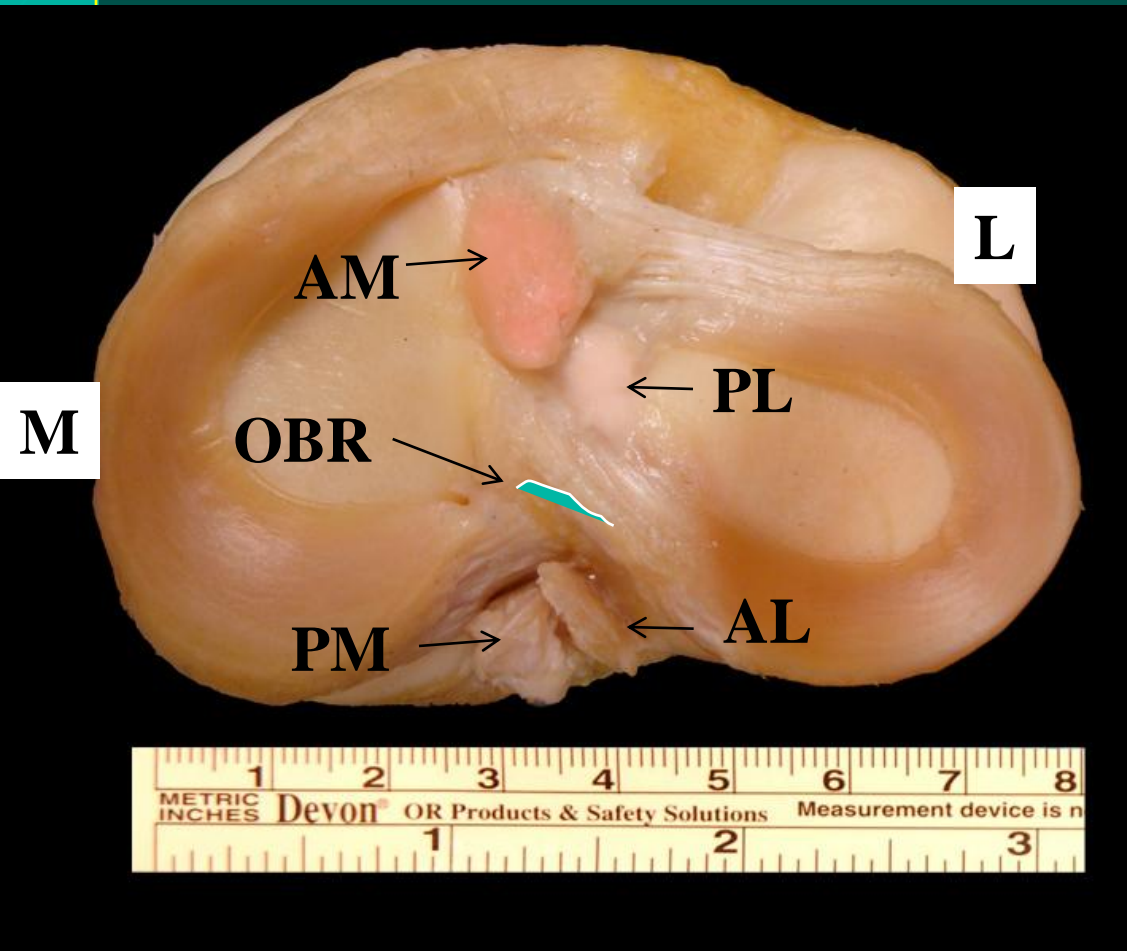
Edwards A, Bull AM, Amis AA (2007). Knee Surg Sports Traumatol Arthrosc.



Anatomical studies can make us understand the best position for the tunnels



Anatomical studies can make us understand the best position for the tunnels



Purpose

- The purpose of this study is to measure the distance between the over-the-back ridge (OBR) and the centroid ACL and posterior border of the PLB on tibial site.



Materials and Methods

- 11 Human Cadaver Knees
- Dissection of the knees
- Anatomical structures marked and outlined using small pins
- AM and PL bundles are identified and divided by their tension pattern under manual knee motion



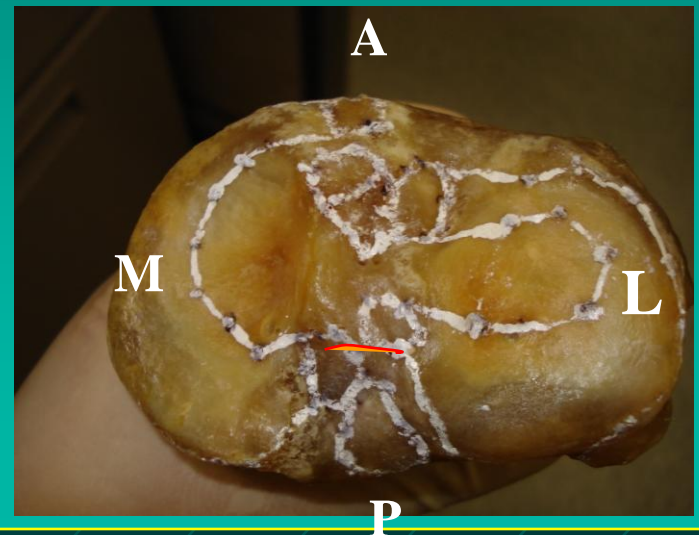
Materials and Methods

- Disarticulation of the knee joint
- Soft tissue will be removed by dissolving them in a 10% sodium hydroxide solution

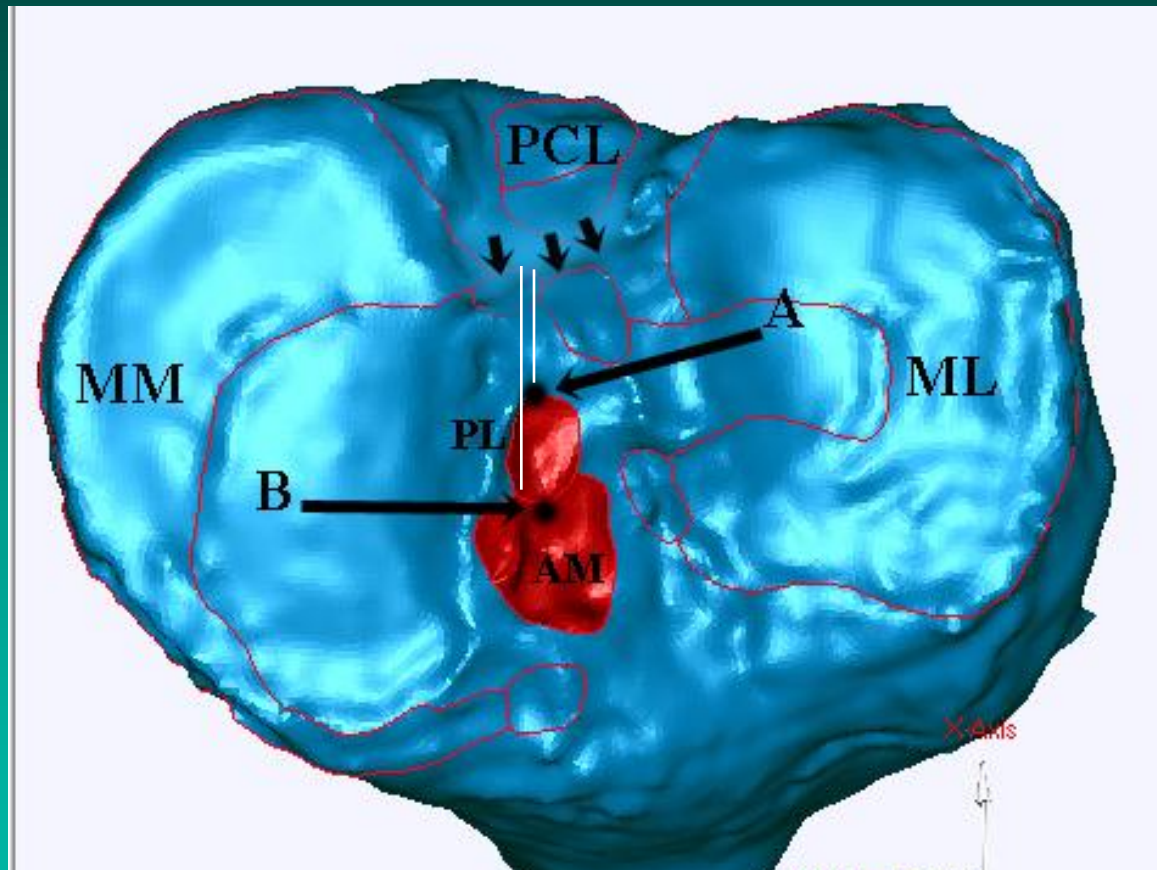


Materials and Methods

- Laser three-dimensional (3-D) scanner (FARO Laser Scan Arm)



Materials and Methods



Measurements of the OBR were taken in the mediolateral direction from the lateral border of the medial tibial eminence, to the centroid of the ACL and OBR to the posterior border of the PLB.

Results

	Mean	SD	Min	Max
Tibial width (mm)	74.2	6.9	60.4	81.6
ACL area (mm ²)	143.5	50.0	143.4	239.2
AM area (mm ²)	90.5	37.5	36.9	168.4
PL area (mm ²)	52.9	17.9	25.6	72.0
ACL length (mm)	16.4	3.3	10.6	22.4
OBR – centroid ACL (mm)	16.8	3.2	11.8	22.6
OBR – PL (mm)	9.8	3.3	5.5	16.3



Discussion

- This study the centroid of the ACL was found positioned 16.8 mm anterior to the OBR.
- The posterior border of the PL to be 9.8 mm distant to the PCL, almost the same distance of the center of the tunnel as published in the past.
- This finding is more anterior than the recommendation of 7mm and 7 -10 mm in the previous literature.

- Morgan CD, Kalman VR, Grawl DM (1995). *Arthroscopy*.
- McGuire DA, Hendricks SD, Sanders HM (1997). *Arthroscopy*.



Discussion

- Wide variation was found in ACL attachment shapes and sizes.
- Surgeons should be careful with the position of the tibial guide.
- An individualized surgery should be conducted by measuring the insertion sites and the ACL – PCL distance.



Limitations

- Bias might be introduced to this study - dissections depend on human decisions - although an accurate 3D measurement system has been used.
- Small sample size.



Conclusions

- The distance between the ACL and PCL was found to be larger than commonly believed.
- These findings may assist surgeons to perform ACL surgery in a more anatomical fashion.



Significance of Findings

- Based on this, the authors would recommend caution to determine correct placement of the tibial tunnel, when possible, to use the remnants of the ACL stump.

